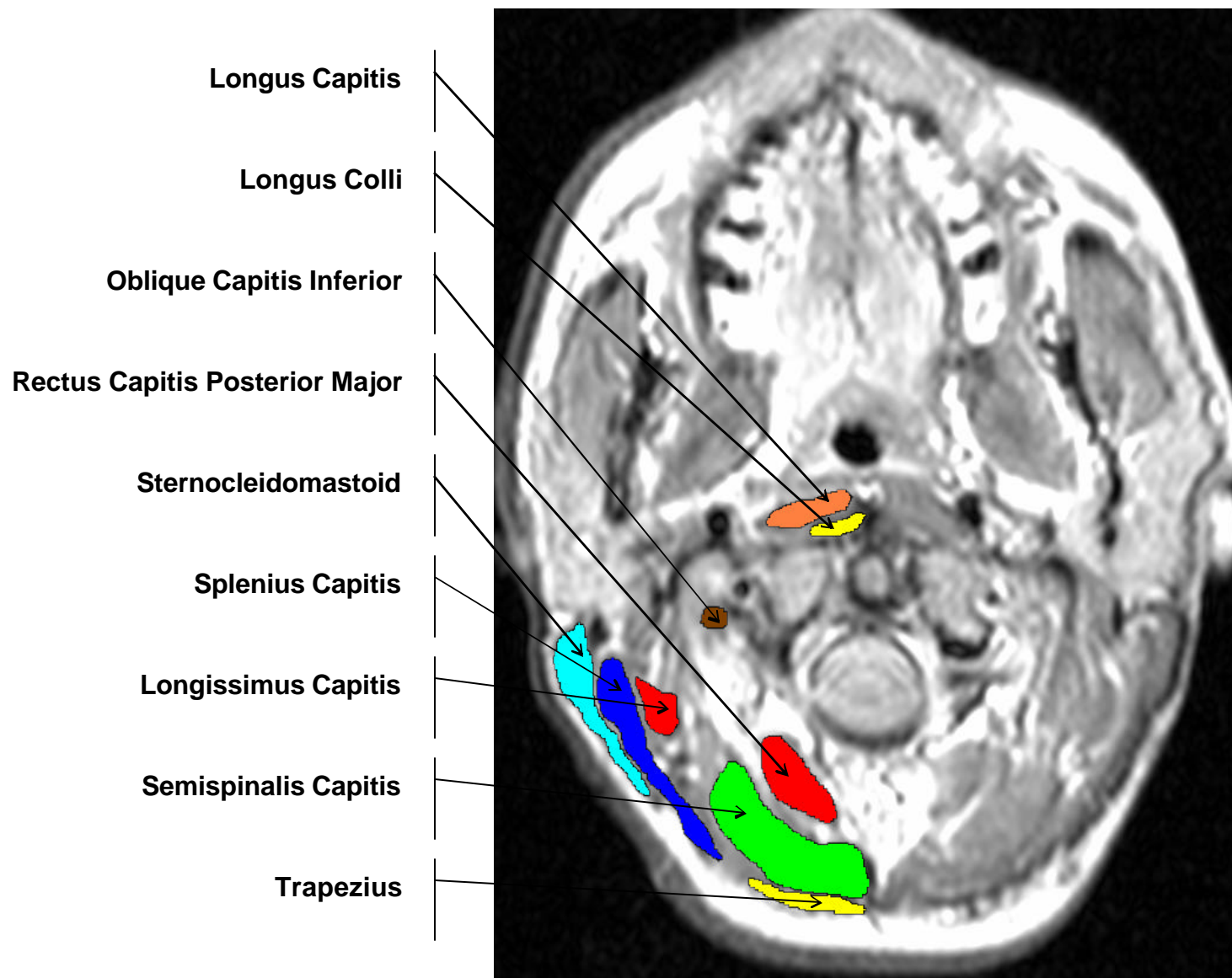
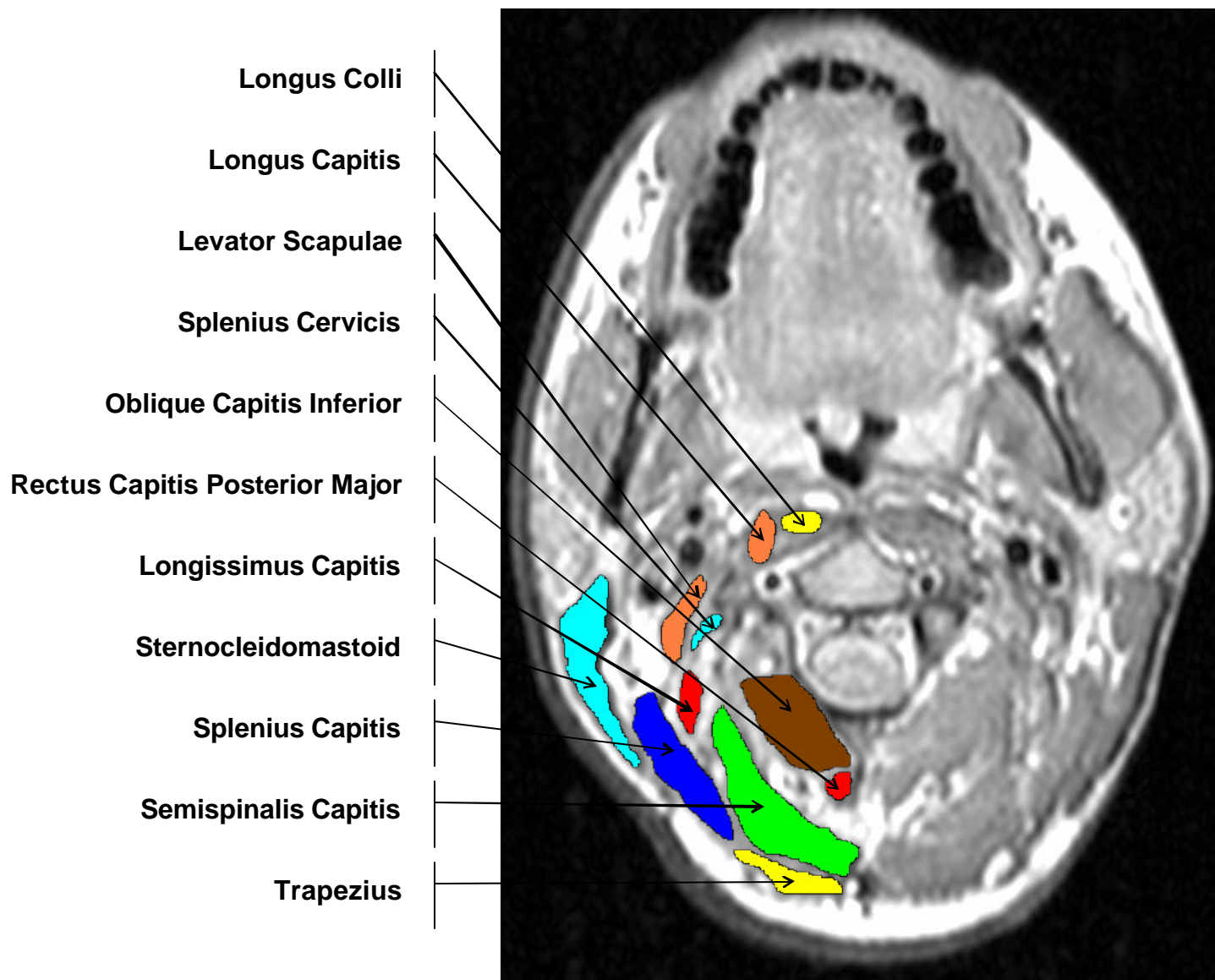


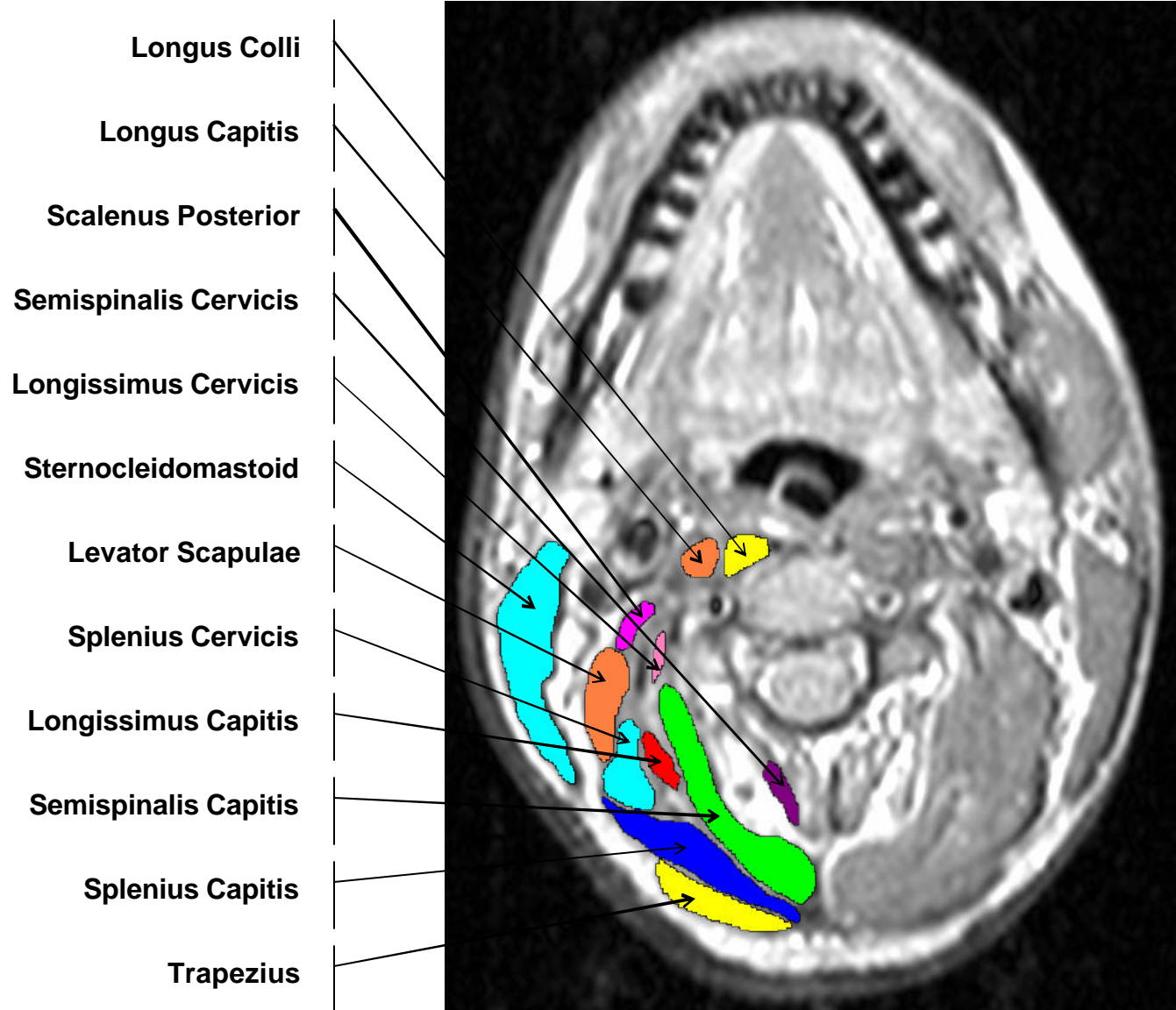
Axial Proton Density Weighted MRI Scan of C1 with Neck Muscles Identified



Axial Proton Density Weighted MRI Scan of C2 with Neck Muscles Identified

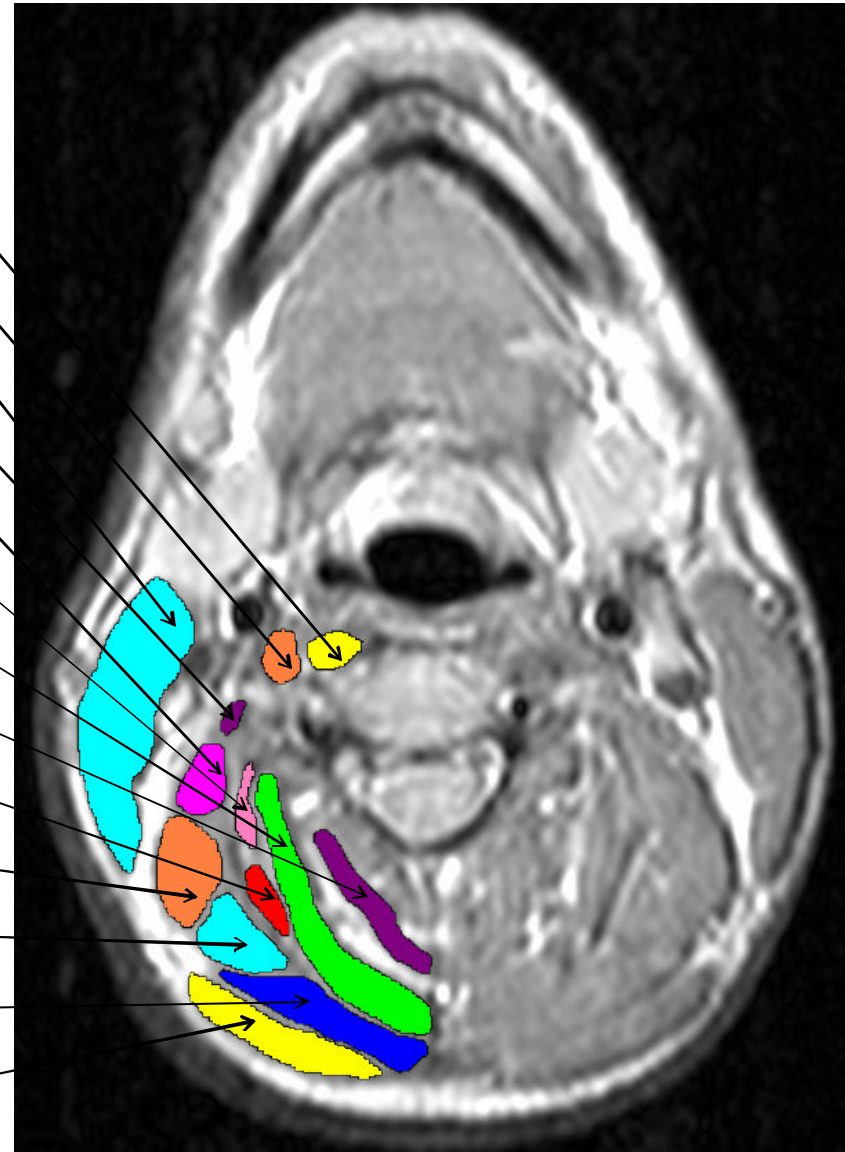


Axial Proton Density Weighted MRI Scan of C3 with Neck Muscles Identified



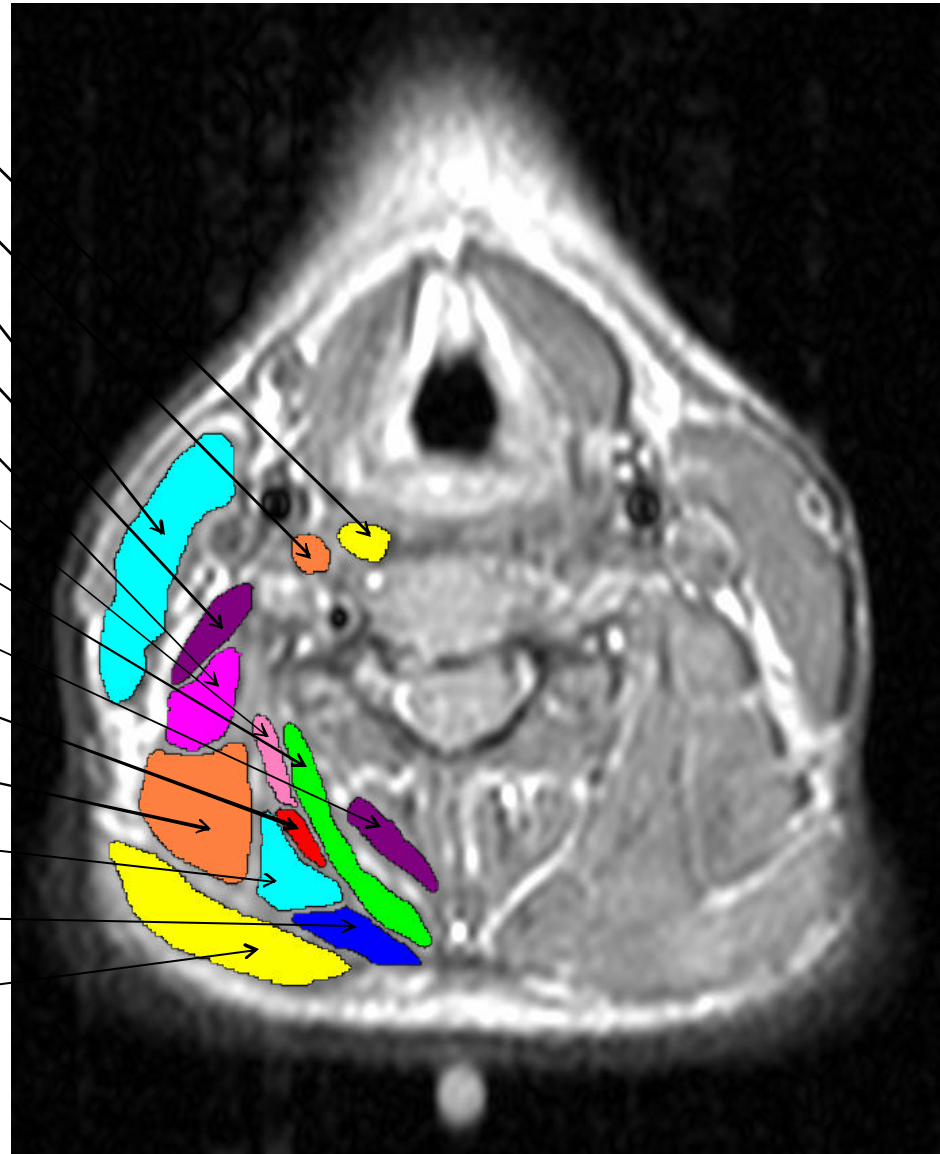
Axial Proton Density Weighted MRI Scan of C4 with Neck Muscles Identified

- Longus Colli
- Longus Capitis
- Sternocleidomastoid
- Scalenus Anterior
- Scalenus Posterior
- Longissimus Cervicis
- Semispinalis Capitis
- Semispinalis Cervicis
- Longissimus Capitis
- Levator Scapulae
- Splenius Cervicis
- Splenius Capitis
- Trapezius



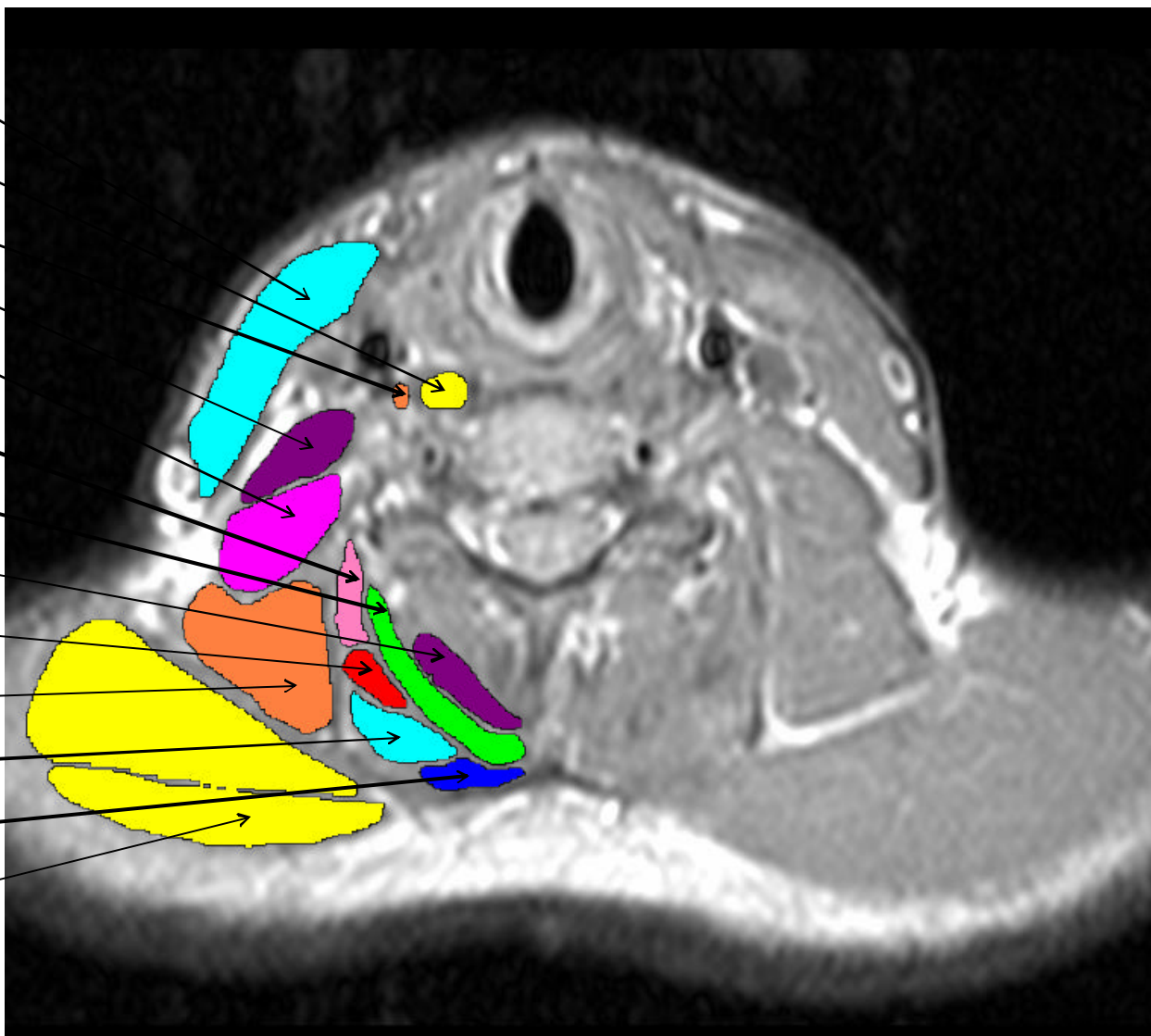
Axial Proton Density Weighted MRI Scan of C5 with Neck Muscles Identified

- Longus Colli
- Longus Capitis
- Sternocleidomastoid
- Scalenus Anterior
- Scalenus Posterior
- Longissimus Cervicis
- Semispinalis Capitis
- Semispinalis Cervicis
- Longissimus Capitis
- Levator Scapulae
- Splenius Cervicis
- Splenius Capitis
- Trapezius



Axial Proton Density Weighted MRI Scan of C6 with Neck Muscles Identified

- Sternocleidomastoid
- Longus Colli
- Longus Capitis
- Scalenus Anterior
- Scalenus Medius and Posterior
- Longissimus Cervicis
- Semispinalis Capitis
- Semispinalis Cervicis
- Longissimus Capitis
- Levator Scapulae
- Splenius Cervicis
- Splenius Capitis
- Trapezius



Axial Proton Density Weighted MRI Scan of C7 with Neck Muscles Identified

